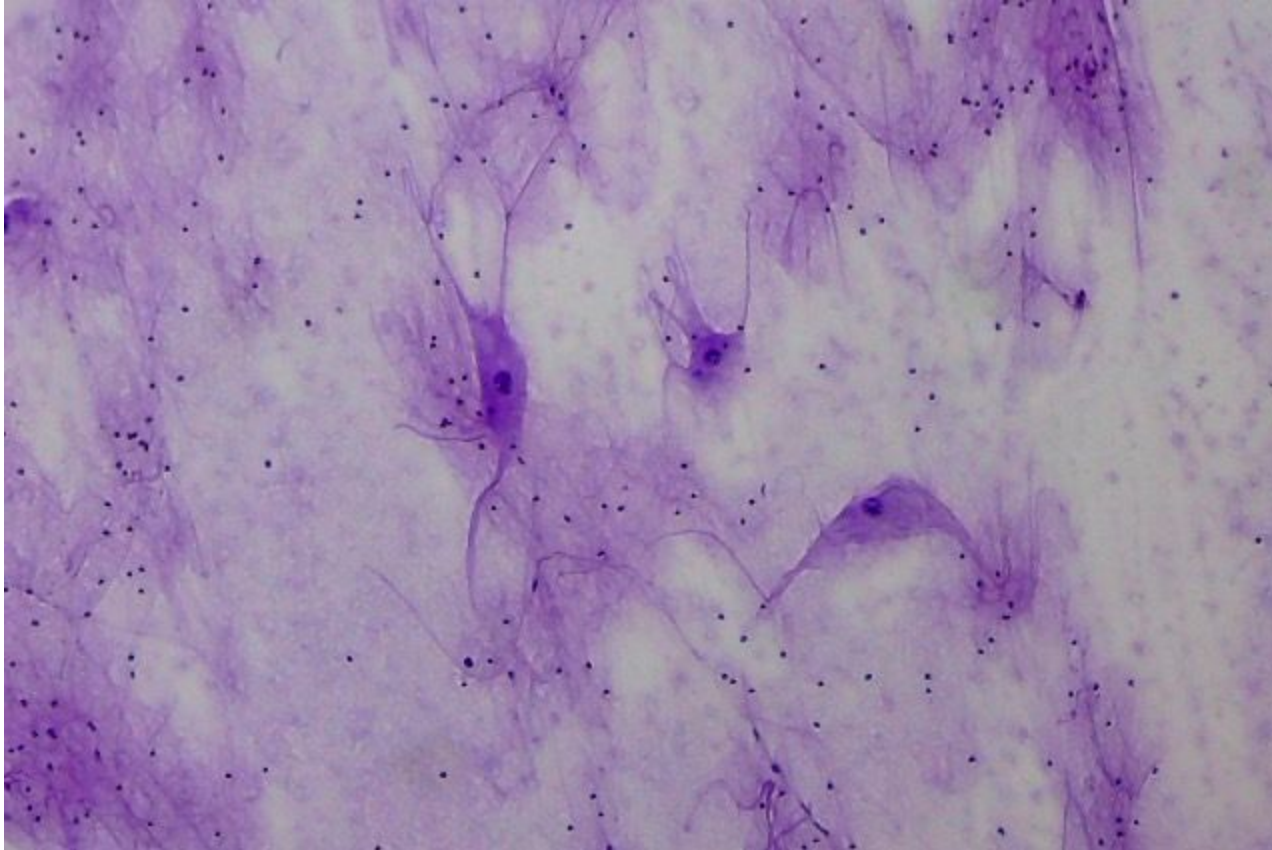
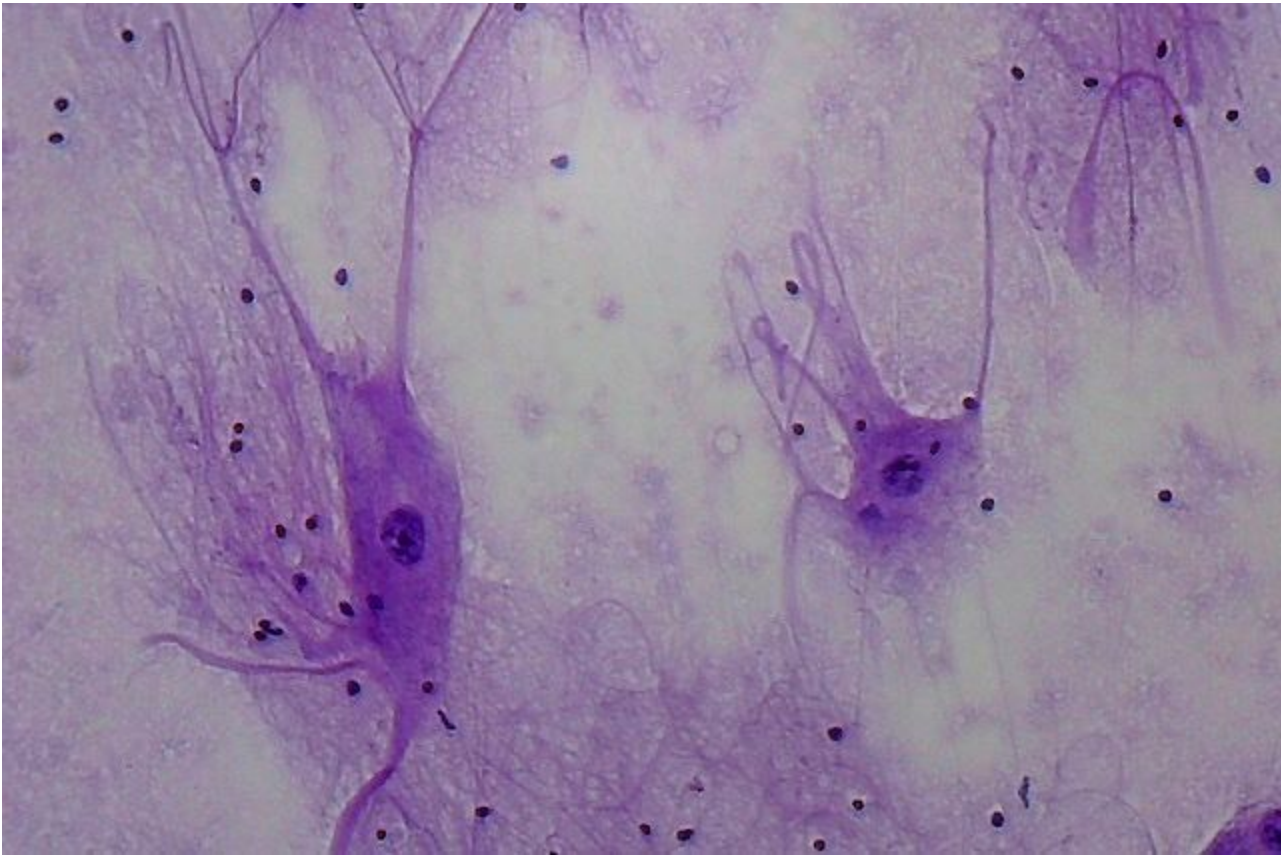


# Microscopic Images of Nerves

Nerve smear at low magnification



Nerve smear at medium magnification



Nerve smear at high magnification

